

## Pathology Recapitulates Embryology: A Case of Duct Ectasia in Pseudomamma

Vani D.<sup>1</sup>, Meghana P.<sup>2</sup>, Sushma M.<sup>3</sup>, Bharathi M.<sup>4</sup>

<sup>1</sup>Professor <sup>2</sup>Post Graduate Student <sup>3</sup>Professor and Head, Department of Pathology, Mysore Medical College and Research Institute, Irwin road, Mysore, Karnataka 570001, India.

### Abstract

From axilla to groin, accessory breast tissue can present anywhere along the milk line. It can harbour all the pathological conditions as that of the normal breast though incidence is very low. Though the accessory breast and duct ectasia are very common entities presenting separately, coexistence is a rarity. In this case report, a 35 year old female presented with a bilateral painless axillary mass. Ultrasonography and FNAC were reported as lipoma. However, the excision biopsy of the same showed duct ectasia in the right axillary swelling. This case report here shows us the possibility of simultaneous coexistence of accessory breast with duct ectasia with a normal breast finding, however rare it might be.

**Keywords:** Accessory Breast; Axilla; Duct Ectasia.

### Corresponding Author:

Meghana P., Post Graduate Student,  
Department of Pathology, Mysore Medical  
College and Research, Institute, Irwin Road,  
Mysore, Karnataka 570001, India.

E-mail: [meghanap.mp@gmail.com](mailto:meghanap.mp@gmail.com)

Received on 05.12.2018,

Accepted on 03.03.2019

### How to cite this article:

Vani D., Meghana P., Sushma M. et al. Pathology Recapitulates Embryology: A Case of Duct Ectasia in Pseudomamma. Indian J Pathol Res Pract. 2019;8(2):238-241.

### Introduction

Polymastia or supernumerary or accessory breast are frequently used terms for ectopic breast tissue which is an aberration of normal breast development. It can present anywhere along the milk line, which extends from axilla to groin and is subjected to the same alterations and diseases, whether benign or malignant, that affect normal breast tissue [1].

The incidence of the accessory breast in females is about 0.4-6%, axilla being the most common site [2]. Duct ectasia, though a common disease of normal breast, it is rare in accessory breast and only a few cases have been reported in the literature. Extensive literature search doesn't yield the exact incidence of this rare occurrence which has prompted us to report the duct ectasia in the axillary accessory breast.

Mammary duct ectasia is also known by different names like comedo mastitis, stale milk

mastitis, mastitis obliterans, varicocele tumor, chemical mastitis or periductal mastitis. It is a benign condition characterized by dilatation of the mammary ducts. Probably, different components of stagnant colostrum elicit localised responses in most of the cases. About 2-6% of women and 1-3% of males present with this condition. Duct ectasia is commonly seen in multi-parous, post-menopausal women in 5th/6th decade of their life. Haagensen described that duct entasia begins with terminal collecting duct dilatation beneath the nipple-areola, with subsequent distension with cellular debris and lipoid containing material. The most common clinical presentation is nipple discharge which is spontaneous, intermittent and frequently bilateral. The material distending the ducts irritates and causes thickening of the duct walls by fibrosis and by an inflammatory infiltration of lymphocytes as the disease progresses [3]. The inflammation is entirely periductal, confining itself to the large sub-areolar ducts. Progressive periductal fibrosis develops with the advancement of the disease with eventual obliteration of the duct lumen. Atrophy rather than proliferation of the epithelium of the involved ducts is the rule. Dense collar of fibrous tissue forms the bulk of the much thickened duct wall with a zone of lymphocytic infiltration demarcating the duct from surrounding fatty breast stroma [4].

Calcifications on mammogram appear as tubular, annular and linear shadows. The ultrasonography allows to measure the duct diameter. While the surgical options are microdochectomy or cone excision of major ducts, the usual treatment regimen remains conservative.

### Case Report

A 35-year-old multi-parous female presented to the OPD with complaints of a painless, progressively enlarging swelling in both the axilla for 6 months. On examination, she had a firm, freely mobile, slightly tender, discrete swelling in the axillae. The swelling on both the sides were completely separate from the respective breast. No palpable lump was noted in both the breasts. Ultrasonography and FNAC were reported as lipoma [Fig. 1 and 2]. Systemic examination was unremarkable. She underwent an excision biopsy of both the axillary masses. Peroperatively it was found to be a subcutaneously located lesion and the excised specimen was sent for histopathological examination.

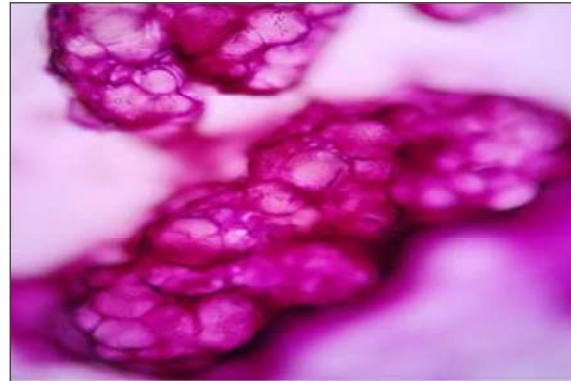

Fig. 1: FNAC of the right axillary swelling showing mature adipocytes in lobules. (H&E, 10X)

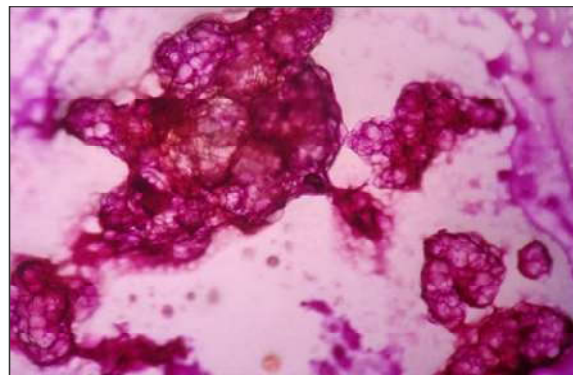

Fig. 2: FNAC of the left axillary swelling showing mature adipocytes in lobules. (H&E, 10X)

### Gross

The right axillary swelling consisted of an irregular partially skin covered fibrofatty tissue, measuring 7x7x4cm. Cut section showed grey white to yellow, lobulated appearance with irregular grey white areas having tiny cystic spaces filled with creamy material [Fig. 3]. The left axillary swelling consisted of an irregular partially skin covered fibrofatty tissue, measuring 6.5x6.5x3cm. Cut section showed yellow fibrofatty tissue [Fig. 4].

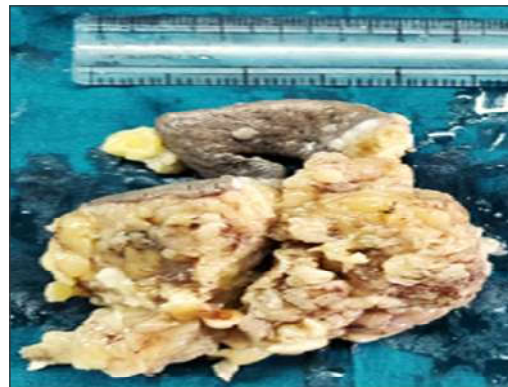
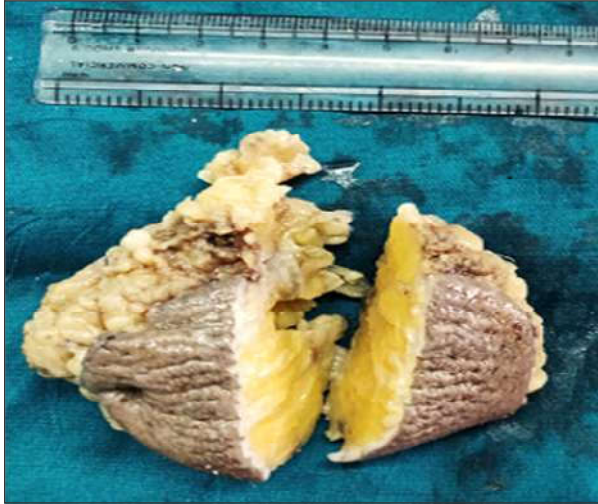
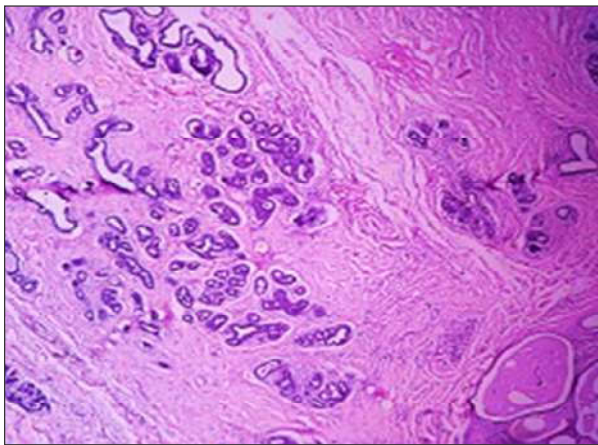
Fig. 3: Gross photograph of the cut surface of the right axillary swelling showing grey-white to yellow areas along with small cystic spaces.



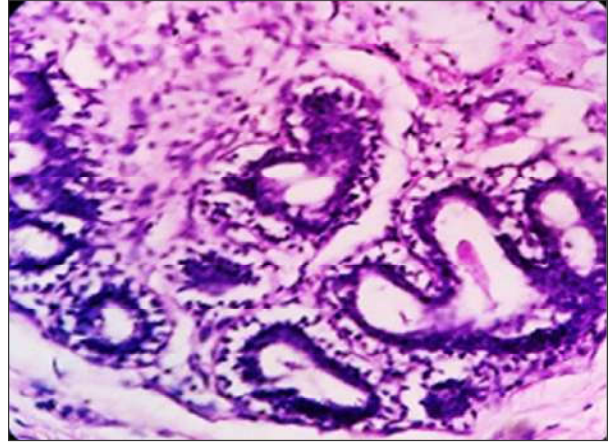**Fig. 4:** Gross photograph of the cut surface of the left axillary swelling showing yellow fibrofatty tissue.

#### *Microscopy*

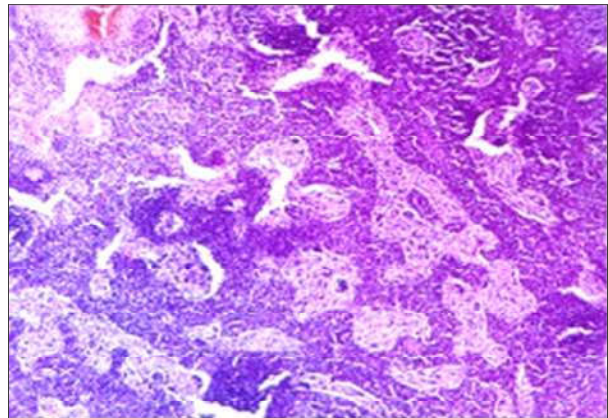
The right axillary swelling showed tissue covered with intact skin. Dermis showed dermal appendages. Subcutaneous fat showed breast tissue with large dilated ducts. Fibrous thickening of the wall with periductal lymphoplasmacytic infiltrate was also seen. Few of the ducts were filled with granular eosinophilic material. Stroma showed variable amount of fibrofatty tissue with lymphoplasmacytic infiltrate and congested blood vessels [Fig. 5 and 6]. Also seen was a lymph node with features of sinus histiocytosis [Fig. 7]. However, no nipple-areola complex was identified. A diagnosis of duct ectasia in accessory breast tissue in the right axilla was given.



**Fig. 5:** Photomicrograph showing large dilated ducts, few of which are filled with granular eosinophilic material. (H&E, 10X)

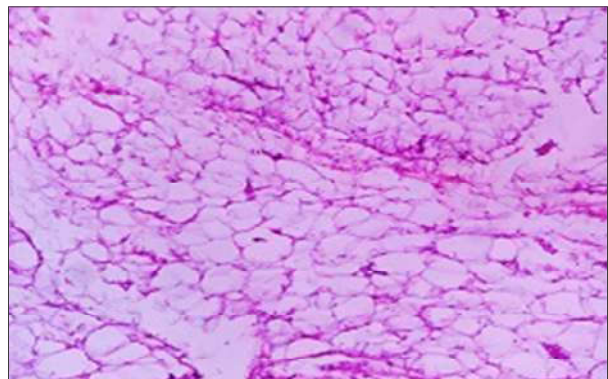


**Fig. 6:** Photomicrograph showing dilated ducts with periductal area and stroma showing infiltration by mononuclear cells. (H&E, 40X)



**Fig. 7:** Photomicrograph showing a lymph node with features of sinus histiocytosis. (H&E, 10X)

Sections studied from the left axillary swelling showed mature adipocytes arranged in lobules, separated by fibrous septa [Fig. 8]. A diagnosis of lipoma in the left axilla was given.



**Fig. 8:** Photomicrograph showing mature adipocytes arranged in lobules, separated by fibrous septa. (H&E, 10X)

## Discussion

Mammary ridges bilaterally develops from the ectoderm during 5th/6th week of embryogenesis and extends along the ventral surface of the body from the axilla to groin. Normally, with the exception of two segments in the pectoral region, which later become breasts, most of the embryologic mammary ridges involute. Failure of the involution of any portion of the mammary ridge can lead to ectopic breast tissue with or without a nipple and areolar complex, which occurs with an incidence of 2-6% in the normal people. The commonest location for such development is the axilla. [5]

Accessory breasts are asymptomatic in most cases, at best causing a visible distension which may resemble a tumor. At times it might cause psychological disturbances in adolescence or even pain and discomfort, especially during menstruation, pregnancy, and lactation. At an incidence of about 0.3%, usually, carcinoma arising in the ectopic breast is rare, but when it presents, does so very late with poorer prognosis due to delay in the diagnosis. To avoid any confusion, all the suspicious masses should better be subjected to cytology or a biopsy from the mass if the cytological evaluation is inconclusive. Surgical excision is considered the treatment of choice as it relieves discomfort [6].

A certain degree of caution is warranted to rule out possible association of extra mammary breast tissue with conditions like supernumerary kidneys, renal agenesis, renal malignancies and other congenital anomalies such as pyloric stenosis, epilepsy and cardiac abnormalities due to corresponding development of mammary tissue and the genitourinary system.

This case gains significance because of the rarity of coexistence of accessory breast with duct ectasia without any primary lesion in the breast,

and also the age of the patient at presentation in the case discussed above was only 35 years and the patient did not have any nipple discharge or the breast lesion. This is in contrast to the usual occurrence of duct ectasia in pre-menopausal or post-menopausal age group with nipple discharge or mass in unilateral or both the breasts.

## Conclusion

This case report emphasizes the importance of considering the ectopic breast and its associated pathology in the differential diagnosis of axillary mass and also stresses the importance of evaluating the patients to rule out renal anomalies or urological malignancies as it is an important association. FNAC is very valuable in diagnosing the lesion but the definitive diagnosis could only be given by histopathologic examination as seen in our case.

## References

1. Tiwary SK, Kumar P, Khanna AK. Fibroadenoma in axilla: Another JMmanifestation of ectopic breast. *BMJ Case Rep.* 2015;2015. pii:Bcr2015209535.
2. Grossl NA. Supernumerary breast tissue: Historical perspectives and clinical features. *South Med J.* 2000;93:29-32.
3. Webb AJ. Mammary duct ectasia – periductal mastitis complex. *Br J Surg.* 1995;82(10):1300-1302.
4. Dixon JM, Ravisekar O, Chetty U, Anderson TJ. Periductal mastitis and duct ectasia: different conditions with different aetiologies. *Br J Surg.* 1996;83(6):820-22.
5. Haagensen CD. Mammary-duct ectasia; a disease that may simulate carcinoma. *Cancer.* 1951;4(4):749-761.
6. Furlong AJ, al-Nakib L, Knox WF, et al. Periductal inflammation and cigarette smoke. *J Am Coll Surg.* 1994;179(4):417-20.